



PATIENT

Marcus Wayne
Animal Shelter

PRESENTING CLINICAL SIGNS

History: Grade 3-4/6 heart murmur. Assess prior to anesthesia for spay.
-Abnormal PE/Chem/CBC/UA Results: WBC 22,100, nutro - 17,459, Mono 663.

SPECIES

Feline

ECHOCARDIOGRAM FINDINGS

2D, m-mode, color flow and doppler imaging is available. The left ventricular wall is normal in dimension. There is a mildly hyperechoic endocardium consistent with mild fibrosis. The papillary muscles are normal in size and hyperechoic. The endocardium appears normal. The left atrium is normal in size. The right atrium is normal in size. The right ventricle appears normal. The mitral valve is normal in structure and mobility. Normal flow through both the RVOT and LVOT. Trace TR. Trace MR. No AI or PI. No pleural or pericardial effusion seen. No obvious cardiac tumors.

BREED

DSH

CARDIAC CHART

SEX

Male

AGE

≈2-3 years

WEIGHT

9.5lbs

INTERPRETED BY

Maggie Machen Lamy,
DVM, DACVIM
(Cardiology)

FELINE CARDIAC PARAMETERS	BODY WEIGHT (kg)	HR (BPM)	IVSd (cm) (Moise, Pipers)	LVIDd (cm) (Moise, Pipers)	LWVd (cm) (Moise, Pipers)	FS (%)	EF (%)
NORMAL PARAMETER	-----	150-240	0.35-0.55	<2 (mean 1.5)	3.5-0.55	35-67	80-100
PATIENT	4.3	188	0.46	1.5	0.46	50	84
FELINE CARDIAC PARAMETERS	LA/AO (Boon)	LA/AO HEART BASE (Swe) (Abbott)	LA 2D short axis Base view (cm) (Abbott)		LVOT VEL (m/s)	RVOT VEL (m/s)	E max (m/s)
NORMAL	<1.5	<1.3	<1.2		<1.6	<1.3	<0.9
PATIENT	1.2	1.1	1.1		1.0	1.2	NM

**Note: All measurements based upon multi-modal images and methods. An average value is reported.
Adapted from June Boon, Veterinary Echocardiography, 1998
Abbott J & MacLean H JVIM 2006;20: 111-119, Moise et al. Am J Vet Res 47:1476, 1986. Pipers et al. Am J Vet Res 40:882, 1979.*

IMAGING PERFORMED BY

Val Shumskaya

INTERPRETATION OF THE FINDINGS & FURTHER RECOMMENDATIONS

Overtly normal cardiac structure and function. The LV wall thickness is normal and there is no evidence of elevated left atrial pressure. No cause for the murmur is identified in this study, making it likely physiologic in origin. No pathology is appreciated.

HOSPITAL NAME

Companion
Veterinary Hospital

Given these findings, no medications are indicated. It is important to note that phenotypic HCM can develop at any phase of life in cats, and often does not accompany a heart murmur or PE abnormalities. Periodic screening is ideally recommended in all cats.

REFERRING VET

Dr. Spitz

No cardiac contraindication for general anesthesia at this time.

INVOICE

32253

Recommend recheck echocardiogram in 1 year to screen for any development of disease that the preexisting murmur may mask.

DATE

8/9/23



PATIENT

Marcus Wayne
Animal Shelter

SPECIES

Feline

BREED

DSH

SEX

Male

AGE

≈2-3 years

WEIGHT

9.5lbs

INTERPRETED BY

Maggie Machen Lamy,
DVM, DACVIM
(Cardiology)

**IMAGING
PERFORMED BY**

Val Shumskaya

HOSPITAL NAME

Companion
Veterinary Hospital

REFERRING VET

Dr. Spitz

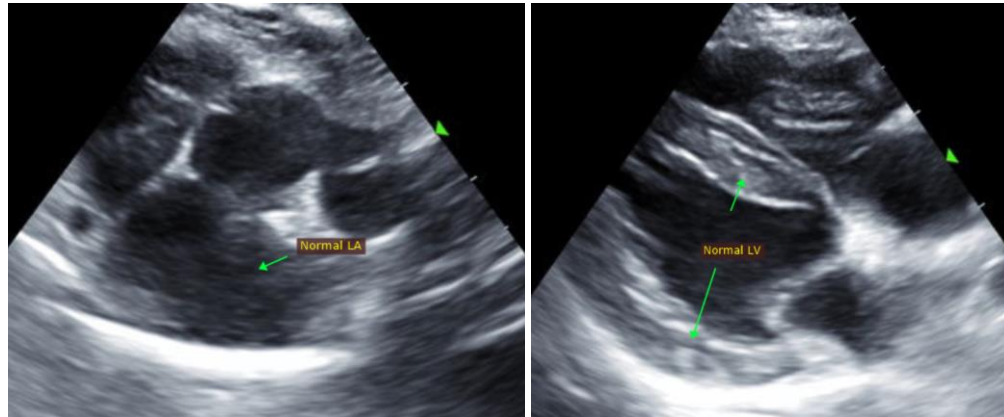
INVOICE

32253

DATE

8/9/23

IMAGES



The information and recommendations provided are based on the images presented by the referring veterinarian. No evaluation can be communicated regarding pathology that was not visible in the image/video clips provided.

Thank you for this referral. This report was generated using transcription software, and minor dictation errors may be present. If the clinical or image interpretation does not parallel your findings or if I can be of any further assistance, please contact me.

Maggie Machen Lamy, DVM
Diplomate of the American College of Veterinary Internal Medicine (Cardiology)
info@sonopath.com